

## Benefits of ultrasound-guided transversus abdominis plane block for open appendectomy in children

Ilona Batko<sup>1</sup>, Barbara K. Kościelniak<sup>2</sup>, Ilona Al-Mutari<sup>1</sup>, Krzysztof Kobylarz<sup>1,3</sup>

<sup>1</sup>University Children's Hospital Jagiellonian University Medical College, Cracow, Poland

<sup>2</sup>Department of Clinical Biochemistry University Children's Hospital, Jagiellonian University Medical College, Cracow, Poland

<sup>3</sup>Department of Anaesthesiology and Intensive Care Jagiellonian University Medical College, Cracow, Poland

### Abstract

**Background:** One of the most frequently performed emergency surgical procedures in children is an appendectomy. The aim of this study was to determine the benefits of supplementing standard, general anaesthesia with the ultrasound-guided right TAP block.

**Methods:** We analyzed the medical records of 90 children of both sexes, aged 4–16 years with a body mass of 16–78 kg who underwent general anaesthesia for open appendectomy. Sixty-two individuals were anaesthetized using the standard method, while 28 patients had an additional right-sided TAP block under ultrasound guidance. Subsequently these groups were divided into 2 subgroups: children under 8 years and those older. We evaluated the total consumption of opioids, intraoperative fentanyl requirement, the amount of non-opioid analgesic and antiemetic drugs used during the whole hospitalization, time to recovery of digestive track function and length of hospital stay.

**Results:** TAP block performed under USG guidance reduced the overall consumption of opioids (0.36 vs. 0.42 mg kg<sup>-1</sup>,  $P = 0.048$ ), significantly shortened time of fasting after the surgery (17 vs. 29 hours,  $P = 0.003$ ) as well as reduced the need for antiemetic drugs: ondansetron were used only in 21.4% of children in the group with TAP block vs. 38.7% of children with standard protocol. Additionally, we noted that the application of the TAP block shortened the length of hospitalization (3 vs. 4 days,  $P = 0.045$ ).

**Conclusion:** The application of the TAP block, as a supplementary treatment to standard general anaesthesia for open appendectomy in children is a valuable component of multimodal analgesia, which might improve the quality of life of the patient and shorten the length of hospitalization.

Anesthesiology Intensive Therapy 2017, vol. 49, no 3, 198–203

**Key words:** appendectomy, regional anaesthesia, children; anaesthetic techniques, transversus abdominis plane block, TAP block; ultrasound-guidance

A surgical removal of the vermiform appendix is one of the most common emergency surgical procedures in children. In recent years, transversus abdominis plane (TAP) block has become more popular as an element of the multimodal analgesia used in abdominal surgery [1]. It was described in 2001 for the first time [2]. Up to now, there have been only a few publications regarding its use in the paediatric population [3, 4]. The aim of this study was to evaluate the advantages of the ultrasound-guided TAP block in children undergoing classic appendectomy.

### METHODS

This retrospective study involved 90 children of both sexes, in the age 4–16 years, weighing 16–78 kg, who received general anaesthesia for classic appendectomy. Moreover, 62 children were anaesthetized using the standard protocol while in 28 patients a right ultrasound-guided TAP block was performed. Both groups were subsequently divided in two subgroups — those up to 8 years and those older. General anaesthesia induction consisted of propofol 2–3 mg kg<sup>-1</sup> or thiopental 3–5 mg kg<sup>-1</sup>, suxamethonium chloride 1 mg kg<sup>-1</sup>

or rocuronium 0.6 mg kg<sup>-1</sup>, fentanyl as needed, followed by tracheal intubation and mechanical ventilation. Sevofluran with oxygen/air or oxygen/N<sub>2</sub>O mixture was given for maintenance of anaesthesia. Standard analgesics were used (acetaminophen, metamizole, ketoprofen and morphine) postoperatively. The TAP block was performed under general anaesthesia — before or after surgery. The ultrasound guided technique was used to identify fascia between the internal oblique and transversus abdominis muscles and assess the spreading of local anaesthetic (0.2–0.5 mL kg<sup>-1</sup>). For local anaesthesia, a mixture of 2% lidocaine and 0.5% bupivacaine with adrenaline 1:200,000 was used in a proportion of 1:1 (1–2.5 mg kg<sup>-1</sup> lidocaine + 0.5–1.25 mg kg<sup>-1</sup> bupivacaine). After surgery, patients were admitted to recovery and afterwards were transferred to a surgical ward.

Based on the medical records total opioid requirement, intraoperative fentanyl requirement, the amount of non-opioid analgesics, the amount of anti-emetic drugs used during hospitalization, time to fluid implementation and duration of hospitalization were calculated. Comparing time of the anaesthesia in both groups, we described how performing of the TAP block influenced time spent in the operating theatre. All observed complications connected with the TAP block were recorded.

### STATISTICAL ANALYSIS

All calculations were made with JMP®, Version 9.0.0 (SAS Institute Inc., Cary, NC, USA). Data were analyzed according to the established statistical standards. Continuous variables were presented as a median and interquartile range (IQR) or

as a mean ± standard deviation while categorical variables were presented as numbers (percentages). Quantitative variables were checked for the normality of their distribution using the Shapiro-Wilk test. Homoscedasticity of variance was assessed using the Levene test. Differences between groups were compared using the Student or the Welch t-test depending on the equality of variances for normally distributed variables. The Mann-Whitney U test was used for non-normally distributed continuous variables. Comparisons of qualitative parameters were conducted using the two-tailed Fisher exact test, or  $\chi^2$  test, as appropriate. Results were considered statistically significant at *P*-values less than 0.05.

### RESULTS

Patients in both groups did not statistically differ in age, body mass or sex. Time of general anaesthesia and time spent in the operating theatre was comparable in both groups. The time difference between surgical and anaesthesiological procedures in the TAP block group was about 10 minutes which corresponds to the average time of performing the TAP block. Length of hospitalization in TAP block group was shorter comparing to the non-TAP block group (3 vs. 4 days, *P* = 0.045) (Table 1).

A lower amount of opioids, calculated with morphine strength (fentanyl = 100 × morphine, nalbuphine = 0.8 × morphine) was used in children with the TAP block (0.36 vs. 0.42 mg kg<sup>-1</sup>, *P* = 0.048).

Simultaneously, the amount of metamizole administered during the perioperative period was statistically lower

**Table 1.** Patient characteristics, surgical and anaesthesiological factors

	without TAP block (n = 62)	with TAP block (n = 28)	<i>P</i> -value
Body mass (kg)	35 (26–50)	30.5 (20.5–42)	0.63
Age (years)	10 (7–13)	8.8 (6.5–12.5)	0.34
Children under 8 years old (n)	18 (29%)	12 (43%)	0.087
Children over 8 years old (n)	44 (71%)	16 (57%)	0.075
Girls (n)	23 (37.1%)	11 (39.3)	0.13
Paracetamol (g kg <sup>-1</sup> )	0.05 (0.04–0.08) n = 61	0.05 (0.03–0.07) n = 27	0.28
Metamizole (mg kg <sup>-1</sup> )	130 (85–180) n = 57	95 (50–110) n = 27	0.017
Ketoprofen (mg kg <sup>-1</sup> )	2.66 (2–4.3) n = 6	3.3 (1.6–5.1) n = 3	1.0
Opioids — morphine strength (µg kg <sup>-1</sup> )	0.42 (0.33–0.50)	0.36 (0.29–0.42)	0.048
Fentanyl (µg kg <sup>-1</sup> )	2.45 (2–2.9)	2.05 (1.59–2.54)	0.058
Time of anaesthesia (min)	70 (65–90)	75 (60–87.5)	0.74
Time of operation (min)	45 (40–60)	40 (27.5–55)	0.1
Time difference between duration of operation and anaesthesia (min)	25 (20–30)	35 (25–35)	0.01
Ondasetron (number) (%)	24 (38.7)	6 (21.4)	0.031
Starting the diet (hours)	29 (18–37)	17 (14–28)	0.003
Hospitalization time (days)	4 (3–6)	3 (3–5)	0.045

**Table 2.** Characteristics of patients under 8 years old, surgical and anaesthesiological factors

	without TAP block (n = 18)	with TAP block (n = 12)	P-value
Body mass (kg)	21 (18–27)	20.5 (18–28.5)	0.13
Girls (n)	7 (38.9%)	5 (41.7%)	0.52
Paracetamol (g kg <sup>-1</sup> )	0.06 (0.05–0.08)	0.05 (0.03–0.09) n = 11	0.68
Metamizol (mg kg <sup>-1</sup> )	160 (115–250)	120 (97.5–160)	0.021
Opioids — morphine strength (µg kg <sup>-1</sup> )	0.4 (0.32–0.55)	0.38 (0.26–0.45)	0.082
Fentanyl (µg kg <sup>-1</sup> )	2.3 (2–3.1)	2.1 (1.54–2.5)	0.84
Time of anaesthesia (min)	65 (65–85)	72.5 (57.5–75)	0.37
Time of operation (min)	40 (40–50)	37.5 (25–47.5)	0.28
Time difference between duration of operation and anaesthesia (min)	25 (25–30)	35 (25–37.5)	0.91
Ondasetron (%)	50	16.7	0.014
Starting the diet (hours)	31 (21–39)	18 (12.5–33)	0.037
Hospitalization time (days)	5 (4–7)	3.5 (3–5)	0.046

**Table 3.** Characteristics of patients over 8 years, surgical and anaesthesiological factors

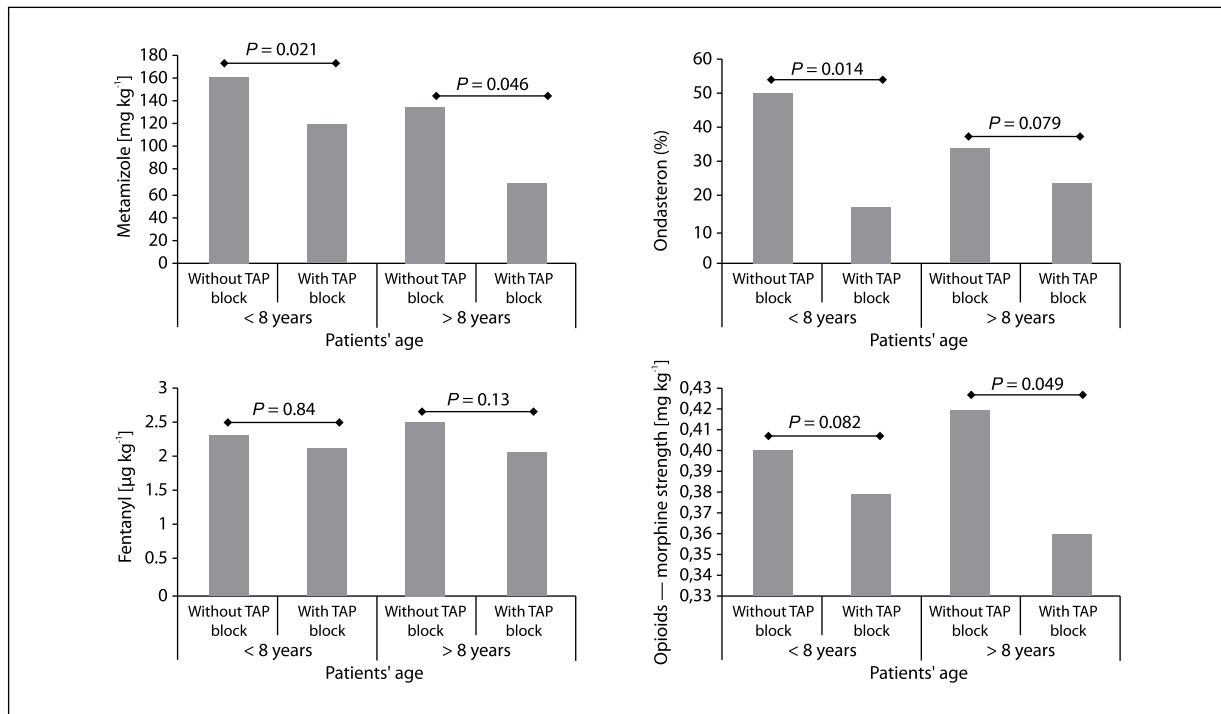
	without TAP block (n = 44)	with TAP block (n = 16)	P-value
Body mass (kg)	43.5 (33.5–54)	37 (30–58)	0.56
Girls (n)	16 (36.4%)	6 (37.5%)	0.032
Paracetamol (g kg <sup>-1</sup> )	0.05 (0.03–0.08) n = 43	0.05 (0.03–0.06)	0.42
Metamizole (mg kg <sup>-1</sup> )	135 (50–170) n = 39	70 (50–95)	0.046
Ketoprofen (mg kg <sup>-1</sup> )	2.7 (2–4.3) n = 6	3.3 (1.6–5.1) n = 3	0.98
Opioids - morphine strength (µg kg <sup>-1</sup> )	0.42 (0.35–0.5)	0.36 (0.31–0.42)	0.049
Fentanyl (µg kg <sup>-1</sup> )	2.5 (2.01–2.9)	2.05 (1.6–2.8)	0.13
Time of anaesthesia (min)	70 (65–90)	75 (62.5–95)	0.79
Time of operation (min)	45 (40–60)	42.5 (30–60)	0.40
Time difference between duration of operation and anaesthesia (min)	25 (20–30)	32.5 (25–35)	0.039
Ondasetron (%)	34.1	25	0.079
Starting the diet (hours)	29 (17.3–35.3)	15.5 (14–25.5)	0.027
Hospitalization time (days)	4 (3–5)	3 (2.5–4.5)	0.048

in the group treated with the TAP block (95 vs. 130 mg kg<sup>-1</sup>,  $P = 0.017$ ). No differences in acetaminophen and ketoprofen dosages were observed. Normal function of the digestive tract was faster restored in children with the TAP block, which was confirmed by a lower requirement for ondasetron (21.4 vs. 38.7%) and a shorter period of fasting after general anaesthesia (17 vs. 29 hours,  $P = 0.003$ ) (Table 1).

Patient under 8 years old did not differ in weight, sex, operation time or requirement for acetaminophen. Small changes were observed in overall opioid and intraoperative fentanyl requirement. Requirements for metamizole (120 vs. 160 mg kg<sup>-1</sup>,  $P = 0.021$ ) and ondasetron (16.5 vs. 50%) were significantly lower in the TAP block patients. Shorter fasting (18 vs. 31 hours,  $P = 0.037$ ) and shorter hospitalization (3.5 vs. 5 days,  $P = 0.046$ ) were noted in this group of patients (Table 2).

Patients over 8 years old did not differ in age, sex or intraoperative requirement for fentanyl and acetaminophen. In the group of children without the TAP block, higher body mass was noticed. In the TAP block group significantly lower total opioid requirements (0.36 vs. 0.42 mg kg<sup>-1</sup>,  $P = 0.049$ ), metamizole use (70 vs. 135 mg kg<sup>-1</sup>,  $P = 0.046$ ) and ondasetron use (25 vs. 34.1%,  $P = 0.014$ ) were observed. The starting of the diet (15.5 vs. 29 hours,  $P = 0.027$ ) and time of hospitalization (3 vs. 4 days,  $P = 0.048$ ) were beneficial in the TAP block group of patients. Moreover, the time of anaesthesia was comparable (Table 3).

Complications of the ultrasound-guided TAP block, such as: hematoma; oedema; puncture of internal organs; puncture of vessels; pulmonary, cardiac or neurological side effects; infection or allergic reaction to administered drugs; were not observed.



**Figure 1.** Requirement for analgesics and anti-emetic drugs in patients with TAP block and without TAP block

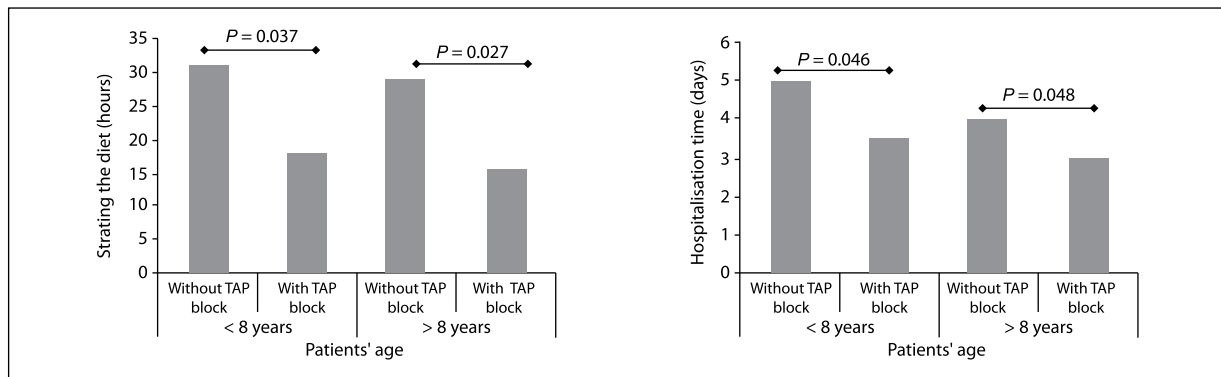
## DISCUSSION

Postoperative pain in children undergoing open appendectomy results mainly from the incision of the antero-lateral part of the abdomen wall, consisting of skin, external and internal oblique muscles, the transversus abdominis muscle and the parietal peritoneum [5]. Six thoracic nerves, along with the first pair of lumbar nerves (anterior branches of eight spinal nerves T6 — L1), supply sensation to this area. They are located between the internal oblique muscle and transversus abdominis muscle in the so-called Transversus Abdominis Plane [6]. The technique of performing the TAP block is to inject local anaesthetic into the transversus abdominis plane, which provides analgesia to the abdomen wall and partial peritoneum below umbilicus line [7]. The ultrasound-guided TAP block technique in children was described for the first time by Suresh in 2009 [8]. There have been reports that larger volume of the local anaesthetic (1–2 mL kg<sup>-1</sup>) may spread to the paravertebral space and extend a range of analgesia, providing partial exclusion of the painful stimuli from the viscera [9]. Previous research results mainly show that the TAP block decreases pain perception, reduces the requirement for analgesics in the postoperative period and increases time span from the end of the anaesthesia to the first dose of analgesics in children after abdominal surgery [3, 10, 11]. However, there are also individual reports which do not confirm this data [12, 13].

While analyzing the intraoperative fentanyl requirement, we need to consider that the TAP block in the investigated group of patients was performed before or after surgery. Furthermore, revision of abdominal cavity after removal of the vermiform appendix causes painful stimuli from the area not embraced with the TAP block. There were no statistically significant differences in intraoperative fentanyl requirement in both groups.

In the TAP block group of patients, a lower opioid requirement during hospitalization was observed, especially in older children. The total amounts calculated for intraoperative fentanyl, intraoperative morphine, morphine and nalbuphine in the postoperative period are presented in Figure 1. In a surgical ward, patients are not under continuous and direct nurse supervision. Because of dreaded opioid side effects, they are not commonly given, especially in younger patients. In case of pain, the most frequently given drug was metamizole. Therefore, we suspect that its use may illustrate a requirement for analgesics. In the TAP block group, its use was significantly lower (Fig. 1).

The reduced need for anti-emetic drugs and the shorter fasting period in the TAP block group of patients shows faster recovery of the digestive tract (Fig. 1, 2). This may be explained by the high quality of analgesia and the lower use of opioids. However, in previous reports concerning children, such a correlation was not observed — a lower requirement for opioids in the TAP block group did not correspond with a decreased incidence of postoperative



**Figure 2.** Starting of diet and time of hospitalization in patients with TAP block and without TAP block

nausea and vomiting. There is no data supporting correlation of a performed TAP block with shortening of the fasting period in patients after open appendectomy [3, 7, 14, 15].

Based on the literature, the TAP block appears to be safe, with minimal number of minor complications (up to 0.3%) requiring no intervention [4, 16]. Data collected in our study confirms this.

According to our data, the time needed for performing the TAP block prolongs time of anaesthesia but not the length of the whole procedure, which is mainly influenced by surgical factors. The duration of anaesthesia was calculated from entry to the operating room to the moment of leaving, while the operating time was calculated from the time of skin incision to that of the wound dressing. It was also observed that children from the TAP block group leave hospital faster (Fig. 2). Previous reports have not noted such a correlation in paediatric patients [3, 15].

Unfortunately, there are limitations of this study. Not only is it retrospective, but there is neither a standard general anaesthesia protocol nor a standard moment of performing the TAP block, along with the fact that the group of patients enrolled in the study is small. No data such as pain perception, intensification of nausea or the patient's comfort level are known. A prospective, randomized study on a larger group of patients is needed in order to define the most effective, and simultaneously the safest dose and volume of a local anaesthetic used for the TAP block. Finally, this also necessary in order to assess its influence on intra- and postoperative analgesia, recovery of digestive tract function and time of hospitalization of children after open appendectomy.

## CONCLUSIONS

Based on data collected in University Children's Hospital in Cracow, it was found that the application of the ultrasound-guided TAP block as a supplementary method of general anaesthesia for open appendectomy lowers the

requirement for opioids and non-opioid analgesics in the perioperative period, speeds recovery of the digestive tract and shortens hospitalization. Performing the TAP block is safe and does not prolong the time spent in the operating theatre.

## ACKNOWLEDGEMENTS

1. Source of funding: none.
2. Conflicts of interest: none.
3. Presentation: Preliminary data were presented during XVIII Symposium of Anaesthesia and Intensive Paediatric Care in Opalenica, 6–8 October 2016, poster session.

## References:

1. Brogi E, Kazan R, Cyr S, et al. Transversus abdominal plane block for postoperative analgesia: a systematic review and meta-analysis of randomized-controlled trials. *Can J Anaesth.* 2016; 63(10): 1184–1196, doi: [10.1007/s12630-016-0679-x](https://doi.org/10.1007/s12630-016-0679-x), indexed in Pubmed: [27307177](https://pubmed.ncbi.nlm.nih.gov/27307177/).
2. Rafi AN. Abdominal field block: a new approach via the lumbar triangle. *Anaesthesia.* 2001; 56(10): 1024–1026, indexed in Pubmed: [11576144](https://pubmed.ncbi.nlm.nih.gov/11576144/).
3. Hamill JK, Rahiri JL, Liley A, et al. Rectus sheath and transversus abdominis plane blocks in children: a systematic review and meta-analysis of randomized trials. *Paediatr Anaesth.* 2016; 26(4): 363–371, doi: [10.1111/pan.12855](https://doi.org/10.1111/pan.12855), indexed in Pubmed: [26846889](https://pubmed.ncbi.nlm.nih.gov/26846889/).
4. Long JB, Birmingham PK, De Oliveira GS, et al. Transversus abdominis plane block in children: a multicenter safety analysis of 1994 cases from the PRAN (Paediatric Regional Anesthesia Network) database. *Anesth Analg.* 2014; 119(2): 395–399, doi: [10.1213/ANE.0000000000000284](https://doi.org/10.1213/ANE.0000000000000284), indexed in Pubmed: [24918899](https://pubmed.ncbi.nlm.nih.gov/24918899/).
5. Wall PD, Melzack R. Pain measurements in humans. In: Wall PD, Melzack R, ed. *Textbook of pain*, 4<sup>th</sup> ed. Churchill Livingstone, Edinburgh 1999: 409–426.
6. Netter FH. Back and spinal cord. In: Netter FH, ed. *Atlas of human anatomy*. The Ciba-Geigy Corporation, Summit, NJ 1989: 145–155.
7. Carney J, Finnerty O, Rauf J, et al. Ipsilateral transversus abdominis plane block provides effective analgesia after appendectomy in children: a randomized controlled trial. *Anesth Analg.* 2010; 111(4): 998–1003, doi: [10.1213/ANE.0b013e3181ee7bba](https://doi.org/10.1213/ANE.0b013e3181ee7bba), indexed in Pubmed: [20802056](https://pubmed.ncbi.nlm.nih.gov/20802056/).
8. Suresh S, Chan VWS. Ultrasound guided transversus abdominis plane block in infants, children and adolescents: a simple procedural guidance for their performance. *Paediatr Anaesth.* 2009; 19(4): 296–299, doi: [10.1111/j.1460-9592.2009.02958.x](https://doi.org/10.1111/j.1460-9592.2009.02958.x), indexed in Pubmed: [19335342](https://pubmed.ncbi.nlm.nih.gov/19335342/).
9. Bergmans E, Jacobs A, Desai R, et al. Pain relief after transversus abdominis plane block for abdominal surgery in children: a service evaluation. *Local Reg Anesth.* 2015; 8: 1–6, doi: [10.2147/LRA.S77581](https://doi.org/10.2147/LRA.S77581), indexed in Pubmed: [25897261](https://pubmed.ncbi.nlm.nih.gov/25897261/).
10. Kendigelen P, Tutuncu AC, Erbabacan E, et al. Ultrasound-assisted transversus abdominis plane block vs wound infiltration in pediatric

- patient with inguinal hernia: randomized controlled trial. *J Clin Anesth.* 2016; 30: 9–14, doi: [10.1016/j.jclinane.2015.12.027](https://doi.org/10.1016/j.jclinane.2015.12.027), indexed in Pubmed: [27041256](https://pubmed.ncbi.nlm.nih.gov/27041256/).
11. Abu Elyazed MM, Mostafa SF, Abdullah MA, et al. The effect of ultrasound-guided transversus abdominis plane (TAP) block on postoperative analgesia and neuroendocrine stress response in pediatric patients undergoing elective open inguinal hernia repair. *Paediatr Anaesth.* 2016; 26(12): 1165–1171, doi: [10.1111/pan.12999](https://doi.org/10.1111/pan.12999), indexed in Pubmed: [27731956](https://pubmed.ncbi.nlm.nih.gov/27731956/).
  12. Fredrickson MJ, Paine C, Hamill J. Improved analgesia with the ilioinguinal block compared to the transversus abdominis plane block after pediatric inguinal surgery: a prospective randomized trial. *Paediatr Anaesth.* 2010; 20(11): 1022–1027, doi: [10.1111/j.1460-9592.2010.03432.x](https://doi.org/10.1111/j.1460-9592.2010.03432.x), indexed in Pubmed: [20964768](https://pubmed.ncbi.nlm.nih.gov/20964768/).
  13. Lapmahapaisan S, Tantemsapya N, Aroonpruksakul N, et al. Efficacy of surgical transversus abdominis plane block for postoperative pain relief following abdominal surgery in pediatric patients. *Paediatr Anaesth.* 2015; 25(6): 614–620, doi: [10.1111/pan.12607](https://doi.org/10.1111/pan.12607), indexed in Pubmed: [25571981](https://pubmed.ncbi.nlm.nih.gov/25571981/).
  14. Niraj G, Searle A, Mathews M, et al. Analgesic efficacy of ultrasound-guided transversus abdominis plane block in patients undergoing open appendicectomy. *Br J Anaesth.* 2009; 103: 601–605.
  15. Sandeman DJ, Bennett M, Dillely AV, et al. Ultrasound-guided transversus abdominis plane blocks for laparoscopic appendicectomy in children: a prospective randomized trial. *Br J Anaesth.* 2011; 106(6): 882–886, doi: [10.1093/bja/aer069](https://doi.org/10.1093/bja/aer069), indexed in Pubmed: [21504934](https://pubmed.ncbi.nlm.nih.gov/21504934/).
  16. Suresh S, De Oliveira GS. Blood Bupivacaine Concentrations After Transversus Abdominis Plane Block in Neonates: A Prospective Observational Study. *Anesth Analg.* 2016; 122(3): 814–817, doi: [10.1213/ANE.0000000000001088](https://doi.org/10.1213/ANE.0000000000001088), indexed in Pubmed: [26579846](https://pubmed.ncbi.nlm.nih.gov/26579846/).

**Corresponding author:**

*Ilona Batko*  
*University Children's Hospital*  
*Jagiellonian University Medical College*  
*ul. Wielicka 265, 30–663 Kraków, Poland*  
*e-mail: ilona.batko@poczta.onet.pl*

*Received: 11.12.2016*

*Accepted: 18.02.2017*