

The effect of ultrasound-guided serratus plane block on the quality of life in patients undergoing modified radical mastectomy and axillary lymph node dissection: a randomized controlled study

Muhammet M. Sulak¹, Ali Ahiskalioglu^{1,2}, Ahmet M. Yayik^{1,2}, Erdem Karadeniz³, Mine Celik^{1,2},
Ufuk Demir¹, Muhammet A. Ari¹, Hacı A. Alici⁴

¹Department of Anesthesiology and Reanimation, Ataturk University School of Medicine, Erzurum, Turkey

²Clinical Research, Development and Design Application and Research Center, Ataturk University School of Medicine, Erzurum, Turkey

³Department of General Surgery, Ataturk University School of Medicine, Erzurum, Turkey

⁴Department of Anesthesiology, Medipol University Faculty of Medicine, Istanbul, Turkey

Abstract

Background: Modified radical mastectomy (MRM) and axillary lymph node dissection (AD) are the most commonly used surgical methods in breast cancer surgery, and they are characterized by moderate to severe pain. This study aimed to investigate the effect of ultrasound-guided serratus plane block (SPB) on postoperative acute and chronic pain in patients undergoing MRM and AD.

Methods: After ethical approval, 60 patients, aged between 18–65 years, ASA I–III, underwent unilateral MRM, and AD was assigned into 2 groups. The SPB group received ultrasound-guided SPB with 30 mL 0.25% bupivacaine, and the control group received 2 mL saline injection subcutaneously. Postoperative analgesia was performed with intravenous patient-controlled analgesia and dexketoprofen trometamol. Pain scores, opioid consumption, and rescue analgesic requirements were recorded. Chronic pain and quality of life were evaluated with the Numerical Rating Scale (NRS), short form-36 (SF-36), and painDETECT.

Results: Compared with the control group, the visual analogue scale scores were statistically lower in the SPB group during 4 postoperative hours in post-anaesthetic care unit PACU at 1st, 2nd ($P < 0.001$), and 4th hour ($P = 0.014$). Fentanyl consumption and rescue analgesics were lower in the SPB group than in the control group (0–4 h, $P = 0.001$; 4–8 h, 8–12 h, 24 h; total $P < 0.001$). The incidence of chronic pain was 11%, and there was no statistically significant difference between control and SPB groups in terms of SF-36, NRS, and painDETECT scores measured at the first and sixth months.

Conclusions: SPB demonstrated superiority versus the control group concerning acute postoperative pain parameters. However, SPB had no influence on the quality of life and did not prevent chronic postmastectomy pain.

Key words: modified radical mastectomy, serratus plan block, chronic pain, pre-emptive analgesia.

Anaesthesiol Intensive Ther 2022; 54, 1: 48–55

Received: 05.03.2021, accepted: 10.08.2021

CORRESPONDING AUTHOR:

Dr. Ali Ahiskalioglu, Department of Anesthesiology and Reanimation, Ataturk University School of Medicine, Erzurum, Turkey, e-mail: aliahiskalioglu@hotmail.com

One of the most common causes of cancer-related mortality in women is breast cancer [1]. Modified radical mastectomy (MRM) is one of the preferred methods in the surgical treatment of breast cancer. In MRM, the breast tissue, fascia of the pectoral major muscle, and level I and II axillary lymph nodes are removed [2]. This surgery is performed with a wide incision and causes moderate to severe postoperative pain. In addition, postoperative chronic pain has been reported in 25–60%

of these patients [3, 4]. Chronic pain has a major negative impact on the quality of life due to the physical limitations and psychological distress it causes. There is also evidence that acute postoperative pain is closely related to the chronic pain experienced in the following months [5]. Therefore, effective postoperative pain management is important not only for the early postoperative period but also for the prevention of chronic pain that will last for months.

Many analgesic protocols are used for pain control after MRM, but none are ideal [6]. For example, intravenous patient-controlled opioid analgesia is commonly used but often associated with nausea/vomiting and excessive sedation [7]. Techniques, such as paravertebral and thoracic epidural blocks significantly reduce postoperative pain scores and opioid consumption, but they are technically difficult to implement and their associated complications, although rare, can be life-threatening [6]. In recent years, ultrasound-guided facial plane blocks have been defined as alternative methods to neuraxial techniques. Pectoral nerve blocks (PECS-I and PECS-II), serratus plane block (SPB), rhomboid intercostal and sub-serratus block (RISS), and erector spinae plane block (ESP) have been shown to be effective in the management of postoperative acute pain in various studies; however, there is only limited available research on their efficacy in chronic pain after breast surgery [8–12].

This primary aim of the presented study was to investigate the influence of ultrasound-guided SPB on postoperative chronic pain at 6 months after surgery in patients undergoing MRM and axillary lymph node dissection (AD). Our secondary objectives in this study were to evaluate postoperative acute pain, opioid consumption, and quality of life of patients.

METHODS

After ethics committee approval of Ataturk University Faculty of Medicine (clinical research assembly number: 6, decision number: 12; date: 24 October 2016), this study was conducted with patients aged 18–65 years, ASA I–III, who were scheduled for selective MRM and AD, did not have known heart disease, kidney disease, liver disease, allergy, or chronic pain, and who agreed to participate in the study. Patients with neurological disease or coagulopathy, those using anticoagulant drugs, those who had not undergone axillary dissection, cases in which surgery was modified after the initial decision, those who could not cooperate, and those with body mass index (BMI) over 35 kg m^{-2} were excluded from the study.

Patients were randomly assigned to one of two equal groups, including 30 patients each, using a computer-generated randomization table (Microsoft Office 365 Excel [Microsoft, Redmond, WA, USA, <http://www.microsoft.com>]) and concealed sealed opaque envelopes. An investigator who had not participated in the subjects opened the sealed opaque envelopes containing the group allocation information. The injected drugs were prepared by an anaesthetist who did not participate in this study and was unaware of the patient group allocation.

All researchers, surgeons, participants, caregivers, and patient outcome evaluators who recorded the postoperative data were unaware of the group assignment. Patients in the serratus plane block (SPB) group received subcutaneously 30 mL of 0.25% bupivacaine, while patients in the control group received 2 mL of saline placebo (saline).

SPB group ($n = 30$): After being taken to the regional anaesthesia room, the patients were provided standard monitoring and placed in the lateral decubitus position with the area to be treated on top. The area to be injected and the high-frequency linear USG probe were prepared under sterile conditions. The ultrasonography probe was placed on the fourth and fifth ribs of the midaxillary line with a longitudinal parasagittal orientation (Figure 1A). The subcutaneous adipose tissue of the skin, latissimus dorsi muscle, serratus anterior muscle, ribs, and pleura were consecutively visualized. A sonovisible nerve block needle was advanced between the latissimus dorsi and serratus muscles using the in-plane orientation (Figure 1B). After it was observed that there was no blood nor air by aspiration, the needle location was confirmed with 1–2 mL of saline, and 30 mL of 0.25% bupivacaine was applied.

Control group ($n = 30$): The patients were positioned as described in the SPB group. Sterilized conditions were met, and ultrasound-guided 2 mL of saline was injected subcutaneously.

After the block procedure, routine general anaesthesia was performed in all patients in both groups using propofol ($2\text{--}3 \text{ mg kg}^{-1}$), fentanyl ($1\text{--}2 \text{ } \mu\text{g kg}^{-1}$), and rocuronium (0.6 mg kg^{-1}) intravenously. Anaesthesia was maintained with 1–2% sevoflurane and 60% N_2O –40% O_2 . After surgery the patients' tracheas were extubated and patients taken to the post-aesthetic care unit (PACU). All surgical procedures were performed by the same surgical team using the same technique.

Postoperative analgesia protocol

The same postoperative analgesia protocol was administered for both groups. All patients were given 50 mg dexketoprofen trometamol intravenously 30 minutes before the end of the surgery. The same dose was repeated every 12 hours postoperatively. A patient-controlled analgesia device (PCA) containing fentanyl was administered in the postoperative recovery room. The PCA was set at a $10 \text{ } \mu\text{g mL}^{-1}$ concentration, with a 50 μg loading dose, 10 minutes lockout time, a bolus of 25 μg , and without basal infusion, and it was left connected for a day. Patients with a Visual Analogue Scale (VAS) score of 4 and above in PACU were administered 25 mg meperidine and noted. A blinded researcher undertook the postoperative follow-up of the cases.

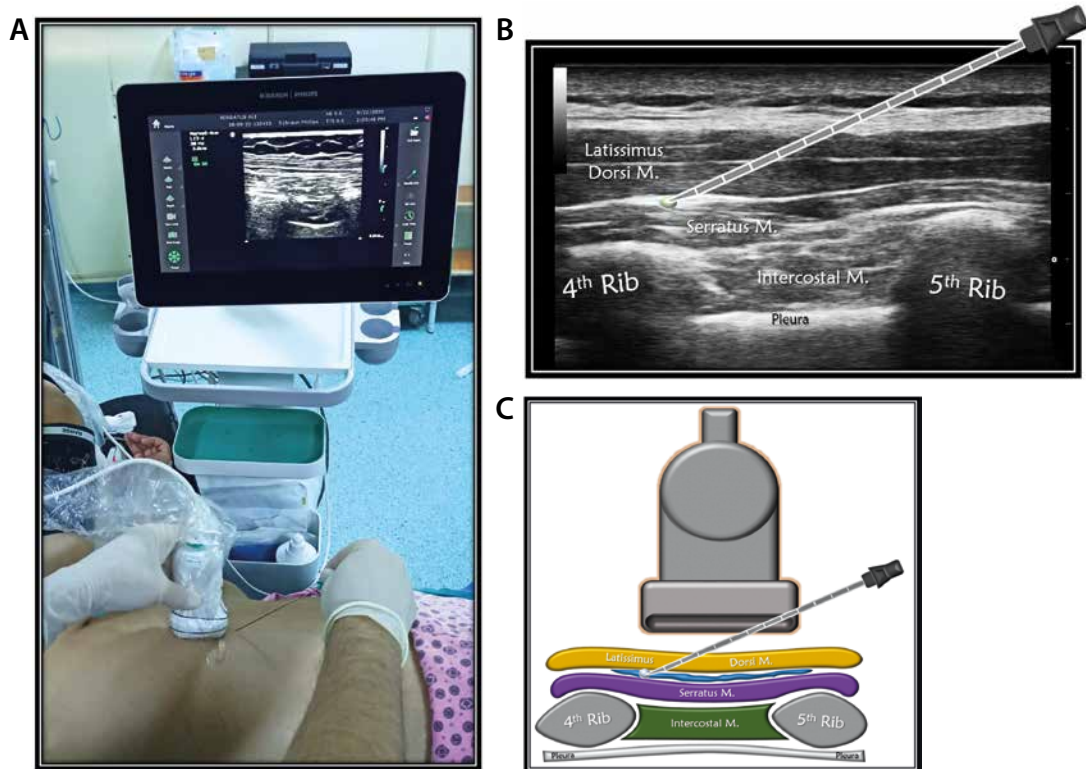


FIGURE 1. A) Patient, ultrasound setup and needle orientation for serratus plane block (SPB). B) Ultrasound anatomy of SPB. C) Basic illustration of SPB

Evaluation of postoperative acute pain

Post-surgical pain assessment was performed by VAS based on a scale of 0 to 10 (0 = no pain, 10 = the most unbearable pain ever experienced). The VAS scores at hours 1, 2, 4, 8, 12, and 24 were recorded in PACU. In addition, the amount of fentanyl intake was recorded for the intervals of 0–4, 4–8, and 8–24 hours, and the total intake was obtained for the 24-hour period. The time to first analgesic requirement was defined and recorded as the time when the VAS score was ≥ 4 . In addition, postoperative opioid-related side effects, such as hypotension, vomiting, and nausea were noted.

Evaluation of chronic pain and quality of life

After surgery, persistent pain was evaluated using a numerical rating scale (NRS) (0: no pain, 10: worst pain imaginable) at the postoperative first and sixth months. The painDETECT questionnaire (PDQ) characteristics were assessed, consisting of 9 items, without requirement of an additional point-of-care clinical examination. A multi-centre study showed that PDQ had 85% sensitivity, 80% specificity, and 83% accuracy in classifying pain as neuropathic and nociceptive [13]. The PDQ has been officially validated in a Turkish population, which was also used in the current study [14]. A score between 0 and 38 is calculated from 9 questions in PDQ, with higher scores indicating a higher likelihood of neuropathic pain. A PDQ score of 0–12 indicates nocicep-

tive pain (probability of a neuropathic pain component $< 15\%$), a score between 13 and 18 is uncertain (an indeterminate neuropathic pain component may be present), and a score between 19 and 38 indicates possible neuropathic pain ($> 90\%$).

The quality of life and general health status of the patients were evaluated using the Short Form-36 (SF-36) at the postoperative first and sixth months. The SF-36 is a questionnaire with 8 subscales, which provides information about a person's health status and quality of life. The SF-36 was translated into Turkish in 1999. Validation studies have been undertaken in different patient groups [15–17].

Sample size determination and statistical analysis

We determined that we would need 25 patients in each group to have an 85% power to detect a reduction in the rate of chronic pain from 40% to 20%, with 2-sided test at an α probability of 0.05 based on previous studies [18]. We scheduled to enrol 60 participants to account for possible dropouts.

SPSS version 20.0 (SPSS Inc., Chicago, Illinois, USA) program was used for the analysis. The normal distribution of data were checked using a histogram and the Kolmogorov-Smirnov Z test. The independent samples *t*-test was used for normally distributed data, and the Mann-Whitney *U* test was used for non-normality distributed data. For categorical variables, the χ^2 test was used. Intra-group evalua-

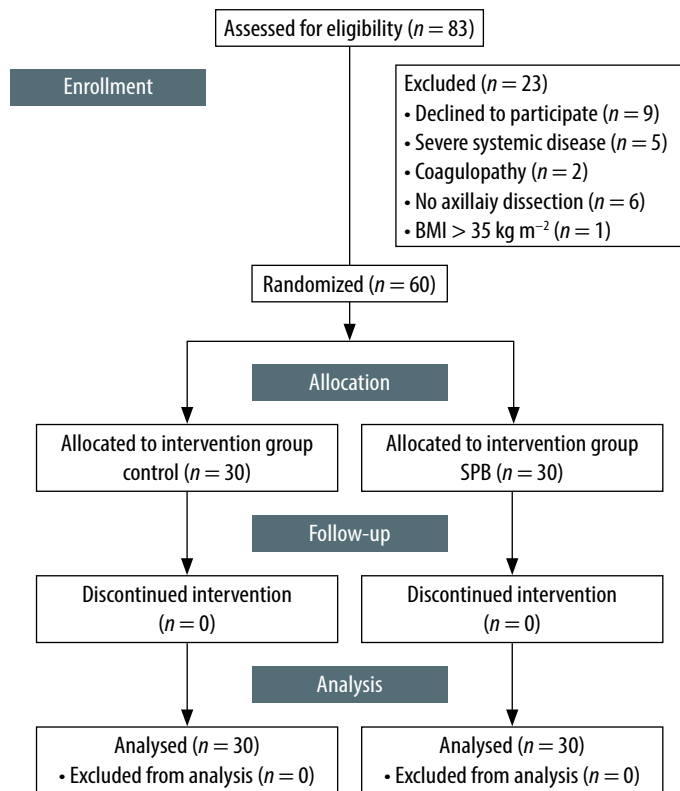


FIGURE 2. Study flow chart (CONSORT)

TABLE 1. Demographic and clinical data of study

Factor	Control group (n = 30)	SPB group (n = 30)
Age (years)	51.07 ± 10.65	52.33 ± 9.14
Body mass (kg)	75.20 ± 8.75	76.87 ± 8.97
Height (cm)	161.07 ± 5.06	159.83 ± 5.13
BMI (kg m ⁻²)	29.09 ± 4.23	29.69 ± 3.24
ASA (II/III)	25/5	26/4
Anaesthesia duration (min)	120.67 ± 27.72	117.00 ± 20.37
Surgery duration (min)	96.67 ± 23.28	90.67 ± 21.12
Incision length (cm)	22.40 ± 4.90	24.50 ± 4.98
Chemoradiotherapy (yes/no)	11/19	10/20

SPB – serratus plane block. Values are presented as mean ± standard deviation or number.

TABLE 2. Acute postoperative pain scores

VAS	Control group (n = 30)	SPB group (n = 30)	P-value
VAS at PACU	4.5 (0–9)	1 (0–6)	< 0.001 ^a
VAS – hour 1	4.5 (0–8)	1 (0–5)	< 0.001 ^a
VAS – hour 2	4.0 (0–7)	2 (0–4)	< 0.001 ^a
VAS – hour 4	4.0 (0–7)	2 (0–5)	0.014 ^a
VAS – hour 8	2.0 (0–7)	2 (0–6)	0.165 ^b
VAS – hour 12	2.5 (0–8)	2 (0–5)	0.195 ^b
VAS – hour 24	2.0 (0–4)	1 (0–3)	0.150 ^b

SPB – serratus plane block. ^aIndependent samples t-test. ^bMann-Whitney U test. All values given as median (minimum–maximum).

tions were undertaken with the paired samples t-test. P-value < 0.05 was considered statistically significant.

RESULTS

Eligible patients for the study were analysed for the primary outcomes. The flow diagram of the study is presented in Figure 2. The demographic data of groups are shown in Table 1. There was no statistically significant difference between the groups in terms of age, weight, height, BMI, ASA classification, duration of surgery, duration of anaesthesia, length of incision, and presence of chemoradiotherapy ($P > 0.05$) (Table 1).

When the postoperative VAS scores of the control and SPB groups were compared, it was determined that these scores were statistically significantly higher in the former than in the latter; measurements were taken at PACU at the 1st, 2nd ($P < 0.001$), and 4th hour ($P = 0.014$). However, there was no statistically significant difference for the VAS scores obtained at hours 8, 12, and 24 ($P > 0.05$) (Table 2).

Postoperative fentanyl consumption was evaluated at the intervals of 0–4 hours, 4–8 hours, and 8–24 hours, and the total consumption was measured at 24 hours. Fentanyl consumption was statistically significantly lower in the SPB group than in the control group at all evaluation times ($P < 0.001$). Also, additional analgesic was required in 10 patients in the control group but only in 3 patients in the SPB group, indicating a statistically significant difference ($P = 0.028$) (Table 3).

In the assessment of persistent postoperative pain, 23% of the patients in the control group and 20% of those in the SPB group had moderate to severe pain (VAS ≥ 4) at the first month ($P = 0.754$) while moderate to severe pain was determined in 16% and 6% of the patients, respectively, at the sixth month ($P = 0.228$) (Table 4).

The neuropathic pain characteristics of the patients were evaluated with PDQ. At the first month, 10% of the patients in both groups showed a high probability of a neuropathic pain component. At this evaluation time, the mean PDQ score was 9 (3–21) for the control group and 8.5 (2–20) for the SPB group, with no statistically significant difference between the groups ($P = 0.764$). When PDQ was evaluated at the sixth month, 10% of the patients in both groups showed a high probability of a neuropathic pain component, with the mean PDQ score being determined as 8 (0–22) and 7.0 (0–22) for the control and SPB groups, respectively ($P = 0.684$) (Table 5).

The general health status and quality of life of the patients were evaluated using SF-36 at the first and sixth months. Accordingly, there was no statistically significant difference between the 2 groups

TABLE 3. Opioid consumption time intervals and rescue analgesia

Factor	Control group (n = 30)	SPB group (n = 30)	P-value
Hours 0–4	105.00 ± 84.18	37.50 ± 28.43	0.001 ^b
Hours 4–8	115.83 ± 86.22	40.83 ± 37.99	< 0.001 ^a
Hours 8–24	114.17 ± 60.06	57.50 ± 56.53	< 0.001 ^a
24-hour total	334.17 ± 184.70	135.83 ± 78.97	< 0.001 ^b
Rescue analgesia (yes/no)	10/20	3/27	0.028 ^a

SPB – serratus plane block. ^aMann-Whitney U test, ^bindependent samples t-test. All values given as numbers or mean ± standard deviation.

TABLE 4. Persistent pain evaluation

Month		Control group (n = 30)	SPB group (n = 30)	P-value ^a
1	Any pain (yes/no)	22 (73%)	23 (76%)	0.766
	NRS ≥ 4 (yes/no)	7 (23%)	6 (20%)	0.754
6	Any pain (yes/no)	25 (83%)	25 (83%)	1.000
	NRS ≥ 4 (yes/no)	5 (16%)	2 (6%)	0.228

SPB – serratus plane block. ^aχ² test. All values given as numbers and percentages.

TABLE 5. PainDETECT scores and neuropathy classification of the study groups

Month		Control group (n = 30)	SPB group (n = 30)	P-value
1	Negative	19 (64%)	21 (70%)	0.825 ^a
	Unclear	8 (26%)	6 (20%)	
	Positive	3 (10%)	3 (10%)	
PainDETECT		9 (3–21)	8.5 (2–20)	0.764 ^b
6	Negative	20 (67%)	22 (73%)	0.807 ^a
	Unclear	7 (23%)	5 (17%)	
	Positive	3 (10%)	3 (10%)	
PainDETECT		8 (0–22)	7.0 (0–22)	0.684 ^b

SPB – serratus plane block. ^aχ² test, ^bindependent samples t-test. All values given as numbers and percentages. Negative: a score of 0–12. Unclear: a score of 13–18. Positive: a score of 19–38.

at the first and sixth months in terms of the SF-36 parameters (*P* > 0.05) (Table 6).

DISCUSSION

This study showed that ultrasound-guided SPB reduced the acute postoperative pain scores,

24-hour opioid consumption, and the need for rescue analgesia compared to the control group in the patients undergoing MRM and AD. On the other hand, the incidence of chronic pain was low and not significantly affected by the pre-emptive SPB.

The innervation of the breast tissue and the axillary region is provided by nerves originating from different regions. While lateral and median pectoral nerves originating from the brachial plexus are responsible for most of the innervation of the pectoralis major and minor muscles, the intercostobrachial, thoracodorsal, and long thoracic nerves play a role in the axillary area. The second and main group of nerves that provide the innervation of the breast tissue are the anterior divisions of the T2–T6 intercostal nerves. The intercostal nerves extend between the internal intercostal muscle and innermost intercostal muscles to the sternum. The lateral cutaneous nerve branch emerges from the midaxillary line, and the pectoral region provides skin innervation up to the parasternal area. The sensation of the parasternal region is supplied by the anterior cutaneous nerves branching from the intercostal nerves [19–21].

SPB is performed at the fourth-fifth rib level at the midaxillary line by injecting local aesthetic along the superficial or deep fascia of serratus anterior muscle, referred to as superficial and deep SPB, respectively. SPB blocks the second to sixth intercostal nerves, as well as the thoracodorsal and long thoracic nerves, and involves the use of anaesthesia in a wide area that includes the T2–T9 dermatome areas and the axillary region in the lateral, anterior, and posterior parts of the thoracic wall. In a study conducted with voluntary patients, Blanco *et al.* [22] showed that almost complete anaesthesia was achieved in the hemithorax where SPB was applied, and superficial SPB (750–840 min) had a longer effect than deep SPB (330–600 min). We also preferred superficial SPB in our study. While the postoperative VAS pain scores were lower in the patients who underwent the SPB procedures compared to the

TABLE 6. Short Form-36 scores of the study groups

Short Form-36	Month 1			Month 6		
	Control (n = 30)	SPB (n = 30)	P-value	Control (n = 30)	SPB (n = 30)	P-value
Physical functioning	57 (30–85)	65 (30–85)	0.536 ^a	75 (15–90)	80 (30–100)	0.371 ^b
Role physical	25 (0–100)	25 (0–100)	0.627 ^b	62 (0–100)	50 (0–100)	0.785 ^b
Role emotional	33 (0–100)	66 (0–100)	0.145 ^b	66 (0–100)	66 (0–100)	0.772 ^b
Vitality	45 (25–65)	52 (15–80)	0.159 ^a	45 (20–75)	47 (10–90)	0.427 ^a
Mental health	68 (32–84)	78 (28–92)	0.445 ^a	68 (28–88)	70 (32–92)	0.125 ^a
Social functioning	37 (0–75)	50 (0–77)	0.287 ^a	68 (0–87)	75 (0–100)	0.109 ^b
Bodily pain	65 (22–90)	65 (20–77)	0.564 ^a	72 (22–100)	77 (20–100)	0.461 ^b
General health	60 (35–95)	65 (25–80)	0.790 ^a	62 (30–95)	65 (20–100)	0.914 ^a

SPB – serratus plane block. ^aIndependent samples t-test, ^bMann-Whitney U test. All values given as numbers.

control group, especially for the first four hours, the mean VAS pain scores were below 4 for all patients at hour 24.

SPB is widely used for postoperative analgesia in breast and thoracic surgery. In a systematic review and meta-analysis examining a total of 1260 patients who underwent 6 thoracic surgical operations and 13 breast operations involving the SPB procedure, Chong *et al.* [23] showed that SPB reduced the postoperative pain scores, prolonged the time to first analgesic requirement, and prevented nausea and vomiting by reducing the postoperative opioid need. In our study, in line with the literature, opioid consumption at all evaluation times and the total opioid requirement were lower in the patients who underwent SPB.

Acute pain is a complex physiological and psychological response to tissue trauma and associated inflammatory processes. This pain arises in response to tissue damage and inflammation and is normally limited to a certain period of time. However, if postoperative acute pain and accompanying physiological processes are not adequately controlled, pain may become chronic [24]. Chronic pain development after breast surgery is multifactorial, and its pathogenesis remains unclear. The psychosocial status of the patient depends on various factors, such as age, obesity, ethnicity, genetics, sensory disorders, lymph node dissection, lymphoedema developing in the chronic period, adjuvant chemo-radiotherapies, and malignancy recurrence. It is also closely related to complications associated with surgery, and in most cases, chronic pain has been attributed to nerve damage. In mastectomy and axillary lymph node dissection, the intercostobrachial nerve and thoracic intercostal nerves can be damaged [25]. During surgery, direct damage to the nerves, such as rupture, compression, ischaemia, stretching, and retraction may develop, or nerve damage may occur later due to traumatic neuroma or scar tissue [26–28].

The main treatment strategy for postoperative chronic pain is to reduce peripheral and central neuronal sensitization and suppress inflammatory responses [29]. Therefore, regional anaesthetic methods are used as a part of multimodal analgesia to prevent and treat chronic postoperative pain, but their efficacy is controversial. In a retrospective study conducted with patients who had undergone an elective inguinal hernia operation, Paasch *et al.* [30] found that the transversus abdominis plane (TAP) block applied for postoperative analgesia could reduce postoperative chronic pain. In contrast, in a prospective study, although the TAP block significantly reduced acute pain, the incidence of chronic pain was not significantly affected [31].

Qian *et al.* [32], comparing the preoperative multilevel paravertebral block with a control group in terms of chronic postmastectomy pain, reported that chronic pain was lower in the paravertebral block group at the postoperative third month (34.5% vs. 51.2%) and sixth month (22.1% vs. 37.2%) compared to the control group. However, studies evaluating the effectiveness of facial plane blocks in chronic pain in breast surgery are limited. Although there is no research in the literature comparing SPB with a control group for chronic pain, one study compared SPB with the PECS-II block. In that study, Fujii *et al.* [33] showed that both blocks were effective in the management of postoperative acute pain. In addition, although the health-related quality of life was similar in the patients who underwent SPB and the PECS-II block at the postoperative sixth month, the rate of moderate-severe pain was found to be lower in the latter (10%) compared to the former (33%). In our study, at the end of the sixth month, we detected an NRS score of ≥ 4 in 11% of all patients, and a PDQ score of 19 and above in 10% of all patients. Furthermore, moderate to severe chronic pain developed in 2 patients in the SPB group and 5 patients in the control group, indicating no significant difference.

In the current study, intravenous dexketoprofen was given to all patients at the end of the surgery, and PCA was applied with fentanyl for 24 hours postoperatively. In addition, postoperative acute pain was well managed in both groups by applying rescue meperidine when necessary. It is known that high pain levels in the early postoperative period are closely related to chronic pain [34]. We consider that the low incidence of chronic pain in our study is closely related to the effective management of postoperative acute pain in both groups.

It is important to investigate preventable factors that play a role in the aetiopathogenesis of chronic pain, in order to increase the quality of life of these patients. The most important of these factors is to reduce surgical complications, especially nerve damage. It is predicted that the risk of nerve damage and chronic pain can also be decreased depending on surgical expertise [35]. It is known that neuralgia due to intercostobrachial nerve injury plays a major role in chronic pain in breast cancer surgery [28]. In our study, we expected less neuropathic pain in the SPB group because this procedure blocked the intercostobrachial nerve, but the number of patients that had a PDQ score of 19 and above, and thus were accepted as positive for neuropathic pain, was equal for both the control and SPB groups. The surgical team that performed all operations in our study has been performing breast surgery for more than 20 years and is specialized in

this field. Therefore, we consider that the low incidence of neuropathic pain in both groups may be related to the experience of the surgical team.

This study has some limitations. First, the preoperative pain scores of the patients due to malignancy were not evaluated. Preoperative pain status may affect postoperative pain scores and opioid consumption. Second, the psychosocial status of our patients was not assessed before the operation. Third, the chemo-radiotherapy protocols could not be fully analysed, and the malignancy recurrence was unknown. Fourth, this study has not been prospectively registered on a database. Lastly, although lymph node dissection was performed in all of our patients, we did not separately evaluate arm-shoulder pain.

CONCLUSIONS

We have shown that ultrasound-guided SPB demonstrated superiority versus the control group with respect to acute postoperative pain parameters as pain scores, opioid consumption, and rescue analgesia. On the other hand, the incidence of chronic pain was low and not significantly affected by the pre-emptive SPB in the patients undergoing MRM and AD. More research is needed with larger sample size and longer follow-up intervals.

ACKNOWLEDGEMENTS

1. Financial support and sponsorship: none.
2. Conflicts of interest: none.
3. Presentation: This study was presented at 37th Annual ESRA Congress (ESRA 2018), Dublin as an oral presentation. Published: https://rapm.bmj.com/content/43/Suppl_1/e42

REFERENCES

1. Bray F, Ferlay J, Soerjomataram I, Siegel RL, Torre LA, Jemal A. Global cancer statistics 2018: GLOBOCAN estimates of incidence and mortality worldwide for 36 cancers in 185 countries. *CA Cancer J Clin* 2018; 68: 394-424. doi: 10.3322/caac.21492.
2. Hermann RE, Steiger E. Modified radical mastectomy. *Surg Clin North Am* 1978; 58: 743-754. doi: 10.1016/s0039-6109(16)41586-0.
3. Gärtner R, Jensen MB, Nielsen J, Ewertz M, Kroman N, Kehlet H. Prevalence of and factors associated with persistent pain following breast cancer surgery. *JAMA* 2009; 302: 1985-1992. doi: 10.1001/jama.2009.1568.
4. Mejdahl MK, Andersen KG, Gärtner R, Kroman N, Kehlet H. Persistent pain and sensory disturbances after treatment for breast cancer: six year nationwide follow-up study. *BMJ* 2013; 346: f1865. doi: 10.1136/bmj.f1865.
5. Katz J, Poleshuck EL, Andrus CH, et al. Risk factors for acute pain and its persistence following breast cancer surgery. *Pain* 2005; 119: 16-25. doi: 10.1016/j.pain.2005.09.008.
6. Chang SH, Mehta V, Langford RM. Acute and chronic pain following breast surgery. *Acute Pain* 2009; 11: 1-14.
7. Mohamed SA, Abdel-Ghaffar HS, Kamal SM, Fares KM, Hamza HM. Effect of topical morphine on acute and chronic postmastectomy pain: what is the optimum dose? *Reg Anesth Pain Med* 2016; 41: 704-710. doi: 10.1097/AAP.0000000000000496.
8. Karaca O, Pinar HU, Arpacı E, Dogan R, Cok OY, Ahiskalioglu A. The efficacy of ultrasound-guided type-I and type-II pectoral nerve blocks for postoperative analgesia after breast augmentation: a prospective, randomised study. *Anaesth Crit Care Pain Med* 2019; 38: 47-52. doi: 10.1016/j.accpm.2018.03.009.
9. Ahiskalioglu A, Yayik AM, Demir U, et al. Preemptive analgesic efficacy of the ultrasound-guided bilateral superficial serratus plane block on postoperative pain in breast reduction surgery: a prospective randomized controlled study. *Aesthetic Plast Surg* 2020; 44: 37-44. doi: 10.1007/s00266-019-01542-y.
10. Yayik AM, Ahiskalioglu A, Ates I, Ahiskalioglu EO, Cinal H. Ultrasound guided bilateral rhomboid intercostal block for breast reduction surgery. *J Clin Anesth* 2019; 57: 38-39. doi: 10.1016/j.jclinane.2019.03.001.
11. Gürkan Y, Aksu C, Kuş A, Yörükoğlu UH, Kılıç CT. Ultrasound guided erector spinae plane block reduces postoperative opioid consumption following breast surgery: a randomized controlled study. *J Clin Anesth* 2018; 50: 65-68. doi: 10.1016/j.jclinane.2018.06.033.
12. De Cassai A, Bonanno C, Sandei L, Finozzi F, Carron M, Marchet A. PECS II block is associated with lower incidence of chronic pain after breast surgery. *Korean J Pain* 2019; 32: 286-291. doi: 10.3344/kjp.2019.32.4.286.
13. Freynhagen R, Baron R, Gockel U, Tölle TR. painDETECT: a new screening questionnaire to identify neuropathic components in patients with back pain. *Curr Med Res Opin* 2006; 22: 1911-1920. doi: 10.1185/030079906X132488.
14. Alkan H, Ardic F, Erdogan C, Sahin F, Sarsan A, Findikoglu G. Turkish version of the painDETECT questionnaire in the assessment of neuropathic pain: a validity and reliability study. *Pain Med* 2013; 14: 1933-1943. doi: 10.1111/pme.12222.
15. Pinar R. Reliability and construct validity of the SF-36 in Turkish cancer patients. *Qual Life Res* 2005; 14: 259-264. doi: 10.1007/s1136-004-2393-3.
16. Kocycigit H, Aydemir O, Fisek G, Olmez N, Memis A. Validity and reliability of Turkish version of Short form 36: a study of a patients with rotatoid disorder. *J Drug Ther* 1999; 12: 102-106.
17. Demiral Y, Ergor G, Unal B, et al. Normative data and discriminative properties of short form 36 (SF-36) in Turkish urban population. *BMC Public Health* 2006; 6: 247. doi: 10.1186/1471-2458-6-247.
18. Juhl AA, Christiansen P, Damsgaard TE. Persistent pain after breast cancer treatment: a questionnaire-based study on the prevalence, associated treatment variables, and pain type. *J Breast Cancer* 2016; 19: 447-454. doi: 10.4048/jbc.2016.19.4.447.
19. Knackstedt R, Gatherwright J, Cakmakoglu C, Djohan M, Djohan R. Predictable location of breast sensory nerves for breast reinnervation. *Plast Reconstr Surg* 2019; 143: 393-396. doi: 10.1097/PRS.0000000000005199.
20. Porzionato A, Macchi V, Stecco C, Loukas M, Tubbs RS, De Caro R. Surgical anatomy of the pectoral nerves and the pectoral musculature. *Clin Anat* 2012; 25: 559-575. doi: 10.1002/ca.21301.
21. Blanco R, Fajardo M, Parras Maldonado T. Ultrasound description of Pecs II (modified Pecs I): a novel approach to breast surgery. *Rev Esp Anesthesiol Reanim* 2012; 59: 470-475. doi: 10.1016/j.redar.2012.07.003.
22. Blanco R, Parras T, McDonnell JG, Prats-Galino A. Serratus plane block: a novel ultrasound-guided thoracic wall nerve block. *Anaesthesia* 2013; 68: 1107-1113. doi: 10.1111/anae.12344.
23. Chong M, Berbenetz N, Kumar K, Lin Ch. The serratus plane block for postoperative analgesia in breast and thoracic surgery: a systematic review and meta-analysis. *Reg Anesth Pain Med* 2019. doi: 10.1136/rapm-2019-100982.
24. Chapman CR, Vierck CJ. The transition of acute postoperative pain to chronic pain: an integrative overview of research on mechanisms. *J Pain* 2017; 18: 359.e1-359.e38. doi: 10.1016/j.jpain.2016.11.004.
25. Jung BF, Ahrendt GM, Oaklander AL, Dworkin RH. Neuropathic pain following breast cancer surgery: proposed classification and research update. *Pain* 2003; 104: 1-13. doi: 10.1016/s0304-3959(03)00241-0.
26. Caffo O, Amichetti M, Ferro A, Lucenti A, Valduga F, Galligioni E. Pain and quality of life after surgery for breast cancer. *Breast Cancer Res Treat* 2003; 80: 39-48. doi: 10.1023/A:1024435101619.
27. Miguel R, Kuhn AM, Shons AR, et al. The effect of sentinel node selective axillary lymphadenectomy on the incidence of postmastectomy pain syndrome. *Cancer Control* 2001; 8: 427-430. doi: 10.1177/107327480100800506.
28. Wallace MS, Wallace AM, Lee J, Dobke MK. Pain after breast surgery: a survey of 282 women. *Pain* 1996; 66: 195-205. doi: 10.1016/0304-3959(96)03064-3.
29. Gilron I, Kehlet H. Prevention of chronic pain after surgery: new insights for future research and patient care. *Can J Anaesth* 2014; 61: 101-111. doi: 10.1007/s12630-013-0067-8.

30. Paasch C, Fiebelkorn J, De Santo G, et al. The transversus abdominis plane block may reduce chronic postoperative pain one year after TAPP inguinal hernia repair. *Ann Med Surg (Lond)* 2020; 55: 190-194. doi: 10.1016/j.amsu.2020.04.011.
31. Theodoraki K, Papacharalampous P, Tsaroucha A, Vezakis A, Argyra E. The effect of transversus abdominis plane block on acute and chronic pain after inguinal hernia repair. A randomized controlled trial. *Int J Surg* 2019; 63: 63-70. doi: 10.1016/j.ijvs.2019.02.007.
32. Qian B, Fu S, Yao Y, Lin D, Huang L. Preoperative ultrasound-guided multilevel paravertebral blocks reduce the incidence of postmastectomy chronic pain: a double-blind, placebo-controlled randomized trial. *J Pain Res* 2019; 12: 597-603. doi: 10.2147/JPR.S190201.
33. Fujii T, Shibata Y, Akane A, et al. A randomised controlled trial of pectoral nerve-2 (PECS 2) block vs. serratus plane block for chronic pain after mastectomy. *Anaesthesia* 2019; 74: 1558-1562. doi: 10.1111/anae.14856.
34. Katz J, Jackson M, Kavanagh BP, Sandler AN. Acute pain after thoracic surgery predicts long-term post-thoracotomy pain. *Clin J Pain* 1996; 12: 50-55. doi: 10.1097/00002508-199603000-00009.
35. Kehlet H. Chronic pain after groin hernia repair. *Br J Surg* 2008; 95: 135-136. doi: 10.1002/bjs.6111.